



Neuroimaging studies in patients with psychogenic non-epileptic seizures: A systematic meta-review



Marco Mcsweeney^{a,*}, Markus Reuber^b, Liat Levita^a

^a Department of Psychology, University of Sheffield, Cathedral Court, 1 Vicar Lane, Sheffield, S1 2LT, United Kingdom

^b Academic Neurology Unit, University of Sheffield, Royal Hallamshire Hospital, Glossop Road, Sheffield S10 2JF, United Kingdom

ARTICLE INFO

Keywords:

Psychogenic Non-epileptic Seizures (PNES)
Dissociation
Diffusion tensor imaging (DTI)
Magnetic resonance imaging (MRI)
Positron emission tomography (PET)
Single photon emission computed tomography (SPECT)

ABSTRACT

Psychogenic Non-epileptic Seizures (PNES) are ‘medically unexplained’ seizure-like episodes which superficially resemble epileptic seizures but which are not caused by epileptiform discharges in the brain. While many experts see PNES disorder as a multifactorial biopsychosocial condition, little is known about the neurobiological processes which may predispose, precipitate and/or perpetuate PNES symptomatology. This systematic meta-review advances our knowledge and understanding of the neurobiological correlates of PNES by providing an up-to-date assessment of neuroimaging studies performed on individuals with PNES. Although the results presented appear inconclusive, they are consistent with an association between structural and functional brain abnormalities and PNES. These findings have implications for the way in which we think about this “medically unexplained” disorder and how we communicate the diagnosis to patients. However, it is also evident that neuroimaging studies in this area suffer from a number of significant limitations and future larger studies will need to better address these if we are to improve our understanding of the neurobiological correlates of predisposition to and/or manifestation of PNES.

1. Introduction

Psychogenic Non-epileptic Seizures (PNES)¹ are episodic functional neurological symptoms which superficially resemble epileptic seizures but which are not caused by epileptic discharges in the brain (LaFrance et al., 2013). Current medical nosologies class most PNES episodes as a manifestation of conversion/somatoform (DSM 5) or dissociative disorder (ICD-10) without providing any additional insights into the likely neurobiological underpinnings of the disorder (American Psychiatric Association, 2013; World Health Organization, 1992). In fact, the traditional dualistic approach to the understanding of functional disorders such as PNES has only provided psychoanalytic/psychodynamic perspectives, characterizing these disorders as “medically unexplained”, and while a host of studies have provided insights into the psychosocial characteristics of PNES (Brown and Reuber, 2016a; Reuber et al., 2007; Wiseman and Reuber, 2015), the biological underpinnings of this disorder have received much less attention.

This is in spite of the fact that many experts see PNES as a

biopsychosocial condition (Reuber et al., 2007; Reuber, 2009) and that patients find it difficult to understand how a physical problem such as a seizure could be caused by “purely” psychological processes or emotional problems. As a result, patients often feel misunderstood, dismissed and stigmatized when they are presented with a psychological model of their disorder (Thompson et al., 2009). In fact, patients may reject their PNES diagnosis altogether due to their subjectively physical seizure experiences on the one hand and their dualistic concept of their condition on the other (Rawlings and Reuber, 2016). One could argue that the relative lack of understanding of PNES from a biological perspective does not only hinder our understanding but also has significant implications for the way in which diagnosis is communicated to patients (Green et al., 2004). However, over the last two decades, researchers have begun to employ novel neuroimaging techniques to investigate the neurobiological correlates of PNES. Like other mental health conditions which are not categorised as “medically unexplained”, we may now be getting closer to providing a neurobiological perspective which may help to improve our understanding of how

* Corresponding author.

E-mail addresses: mmcsweeney1@sheffield.ac.uk (M. Mcsweeney), m.reuber@sheffield.ac.uk (M. Reuber), l.levita@sheffield.ac.uk (L. Levita).

¹ While the authors have concerns with adopting the term psychogenic non-epileptic seizures (PNES), this was done because this was the most commonly used term in the scientific literature presented in this review. However, defining this condition as ‘psychogenic’ necessarily implies a purely psychological mechanism underlying non-epileptic seizures. While the psychological aspects of conversion are very helpful to our understanding and treatment of functional neurological disorders such as PNES, it is not clear if they are always necessary or indeed sufficient for the development or maintenance of this condition. Alternative biological explanations of PNES may provide important additional information, which when presented, should be given due consideration.

<http://dx.doi.org/10.1016/j.nicl.2017.07.025>

Received 28 June 2017; Received in revised form 24 July 2017; Accepted 26 July 2017

Available online 27 July 2017

2213-1582/ © 2017 The Authors. Published by Elsevier Inc. This is an open access article under the CC BY-NC-ND license (<http://creativecommons.org/licenses/by-nc-nd/4.0/>).

neurobiological changes could play a part in the aetiology and maintenance of this disorder.

Although neuroimaging studies focusing on PNES have been summarised previously (Allendorfer and Szaflarski, 2014; Asadi-Pooya, 2015; Baslet, 2011; Perez et al., 2015; Sundararajan et al., 2016), most previous reviews were not systematic and may have missed important studies in this area. In addition, no previous review has sought to uncover convergent neuroimaging findings in patients with PNES to better determine the neurobiological correlates of this condition. To that end, this systematic meta-review provides an up-to-date synthesis and quantification of both structural and functional neuroimaging studies performed on individuals with PNES. Having summarised the research in this area, we provide a critical appraisal of each methodological approach from which the conclusions were derived. This may better inform future research and current theoretical models.

2. Method

2.1. Literature search

The literature search for this review was closed on the 2nd of May 2017. The search terms used to identify relevant publications were ‘dissociative seizure*’ OR ‘non-epileptic attack disorder’ OR ‘non-epileptic seizure*’ OR ‘psychogenic non-epileptic seizure*’ OR ‘conversion seizure*’ OR ‘pseudoseizure*’, AND ‘MRI’ OR ‘fMRI’ OR ‘imaging’ OR ‘neuroimaging’ in the Web of Science core collection (1960–May 2017; 189), ovid Medline (1960 to May 2017; 209), and Psycinfo (1960 to May Week 1 2017; 392). Our initial literature search identified a total of 790 publications. After a multistage selection process 17 empirical publications were retained and form the basis of this review (Fig. 1).

2.2. Quality assessment of studies

Due to the absence of a suitable rating system specific to studies in this area, a bespoke rating system was employed. This rating system is similar to one used recently by Brown and Reuber (2016a) and was adapted with neuroimaging of patients with PNES specifically in mind. The ratings are based on the proportion of “yes” responses to the following criteria; 1) video-EEG confirmed PNES diagnosis; 2) comparison groups matched for age and gender; 3) patients with mixed diagnosis (PNES plus epilepsy) excluded from the PNES group. If not, was this group compared to a PNES group free of a mixed diagnosis (PNES with no epilepsy); 4) co-existing psychiatric conditions excluded from the PNES group; 5) other central nervous system pathologies excluded from the PNES group; 6) other functional neurological disorders excluded from the PNES group; 7) effects of medication controlled for; 8) image acquisition and analysis discussed in sufficient detail to allow for study replication. The final item relates to sample size. Studies with group sizes ≥ 50 were rated as good, studies with group sizes between 16 and 49 were rated as moderate, and studies with group sizes ≤ 15 received a poor rating.

The overall rating was based on the summation of “yes” responses to items 1–8 in addition to weighted scores for sample size. Each item was assigned a score of 0.1 for yes and 0.0 for no, with the exception of sample size (item 9) which was given the score of 0.0 for poor, 0.1 for moderate and 0.2 for good. Therefore, the highest possible rating was 1.0. In addition, studies that reported on the prevalence of brain abnormalities in PNES groups relating to lesions, tumours, evidence of stroke, cysts etcetera were given a score of 0.1 for item 5 (other central nervous system pathologies excluded from the PNES group). It was not deemed appropriate to mark these down when the presence of neurological/CNS pathologies was the primary focus of these studies. In cases in which it was unclear whether or not a study met any of the items described above or where only some of the participants but not all met these criteria, a score of 0.0 was allocated. These ratings were then used to assess the overall quality of the respective research methodology

from which the conclusions were derived. Studies with ratings ≥ 0.8 (based on yes item response, score of 0.8 out of 1.0) were rated as high quality. Studies with ratings between 0.5 and 0.7 were rated as moderate and those with ratings between 0.2 and 0.4 were rated as poor.

2.3. Meta-analyses

Nine of the seventeen studies included in this review were eligible for inclusion in our meta-analysis (Table 1). Given that a number of different neuroimaging approaches were used and in order to identify which brain regions were most consistently implicated in PNES across these studies, we conducted a coordinate-based Activation Likelihood Estimation (ALE) meta-analysis using GingerAle 2.3.6 (Eickhoff et al., 2009, 2012; Turkeltaub et al., 2012).

This method is capable of integrating findings from multiple imaging modalities and to identify converging brain areas across different experiments/different contrasts and statistically determines whether the convergent brain areas or clusters reported are greater than expected by chance. All available coordinates were transformed from MNI space to Talairach space using icbm2tal transform (Laird et al., 2010; Lancaster et al., 2007) provided by brainmap.org (Eickhoff, 2014). Given that this was an exploratory analysis, and as noted by Eickhoff et al. (2012) both uncorrected p values and FDR corrected thresholds are not always optimal, we opted for a less conservative correction by implementing cluster-level inference. This threshold algorithm uses a “cluster-forming threshold” with an uncorrected p value of 0.001 as the cluster-forming threshold with a cluster-level inference of 0.05 with 1000 permutations, as recommended by brainmap.org. Mango (v 4.0) was used to view the threshold maps and the ALE results were superimposed on the high-resolution standard anatomical brain image provided by brainmap.org (Colin_t1rc.nii).

Given that all of the imaging studies entered into our meta-analysis involved group comparisons, we summed the number of PNES patients and the number of participants in the comparison groups to quantify the number of participants in each study. Where studies came from the same research group and used the same participants (Ding et al., 2014; Li et al., 2014, 2015) we subsumed these participants into a single group of coordinate results in order to avoid any overestimation of these participants in the results. Three different meta-analyses were conducted. The first analysis combined both structural and functional findings from all nine studies. The second analyses focused solely on studies reporting functional connectivity patterns in PNES patients compared to healthy controls. The third and final analysis focused solely on imaging studies reporting structural brain differences between PNES patients and controls. All reported foci (MNI or Talairach coordinates) from these publications entered the ALE analysis. In the results, brain areas within $\pm 5 \text{ mm}^3$ of any significant cluster above the corrected p value threshold are also reported.

3. Results/discussion

The results of this review have been divided into three sections. The first section describes the results of the quality assessment. The second section is sub-divided into the different neuroimaging modalities used in which limitations are discussed and future directions proposed. The third section outlines the results of the meta-analyses.

3.1. Quality assessment results and imaging methods

Of the seventeen studies assessed, none were rated as high quality, fourteen were of moderate quality, and three were rated as poor. Eleven (65%) were case control studies and six (35%) adopted a retrospective methodology. Sample sizes were considered good in three (17.6%), moderate in nine (53%) and poor in five studies (29.4%). All studies included both male and female participants, all over the age of 16. Across all seventeen studies the median total sample size was 38 (range

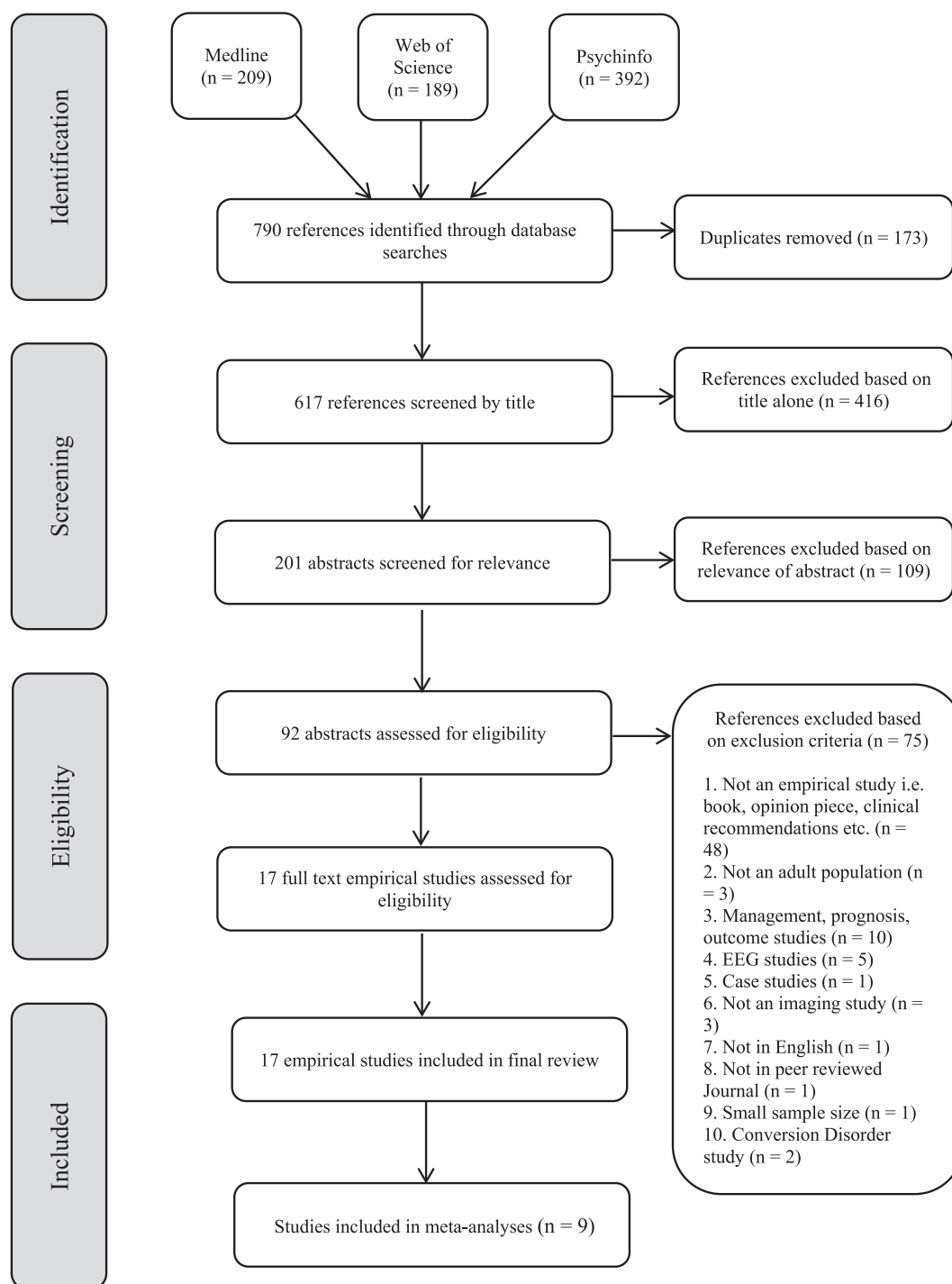


Fig. 1. PRISMA flow diagram showing results of the multistage search process.

13–256, mean 66). The total number of participants was 1004. In total, the studies included 402 patients with PNES (range 8–79, mean 29, median 17). Sample sizes and groups characteristics for each of the seventeen studies are shown in Table 1. Results of the rating system are presented in Table 2. Table 3 summarizes findings and limitations separately for each imaging modality.

3.2. Structural magnetic resonance imaging

3.2.1. Pathological brain changes in patients with PNES

Initial information about possible brain changes associated with PNES can be extracted from studies in which visual inspection of

structural MRI was used to look for potentially pathological brain abnormalities. Indeed, several researchers have identified brain abnormalities such as tumours, cysts, aneurysms, evidence of stroke, white matter lesions, hippocampal sclerosis, venous angioma, and general atrophy in PNES patients with or without epilepsy. The studies described below noted such findings in considerably more patients with PNES than expected in healthy volunteers in whom such findings are identified in 4.8% to 13.6% of cases (Katzman et al., 1999; Vernooij et al., 2007).

Based on an initial sample of 311 patients with a diagnosis of PNES with or without epilepsy, Devinsky et al. (2001) documented cerebral structural or electroencealographic abnormalities in roughly 25.4% of

Table 1
Sample size and group characteristics.

Study	PNES	ES	Healthy controls	PNES + ES	ES + Psych	Non-diagnostic	IED	Total sample	Semiology features (PNES)
Arthuis et al. (2015) ^a	16	-	16	-	-	-	-	32	Dystonic attacks with primary gestural activity, paucikinetic attacks with preserved responsiveness, pseudosyncope
Bolen et al. (2016)	68	111	-	19	-	32	26	256	Major convulsions, tremors, unresponsiveness, subjective.
Devinsky et al. (2001)	79	51	-	-	71	-	-	201	Motor events (seizures), weakness
Ding et al. (2013)	17	-	20	-	-	-	-	37	Hypermotor movements of extremities, trembling, trembling of the extremities
Ding et al. (2014) ^a	18	-	20	-	-	-	-	38	Hypermotor movements of extremities, trembling, trembling of the extremities
Etinger et al. (1998)	11	11	-	-	-	-	-	22	Impaired consciousness
Hernando et al. (2015)	8	-	8	-	-	-	-	16	Major motor events, minor motor events (waxy flexibility), electric feeling back of head followed by inability to talk or move (subjective event)
Labate et al. (2012) ^a	20	-	40	-	-	-	-	60	Convulsive components (tonic-like, clonic-like or bizarre motor manifestations), no non-motor events such as paralysis, sensory feelings or unresponsiveness
Lee et al. (2015) ^a	16	-	16	-	-	-	-	32	Major motor, minor motor, waxy flexibility, subjective events
Li et al. (2014) ^a	18	-	20	-	-	-	-	38	Hypermotor movements of extremities, trembling, trembling of the extremities
Li et al. (2015) ^a	18	-	20	-	-	-	-	38	Hypermotor movements of extremities, trembling, trembling of the extremities
Neiman et al. (2009)	13	-	-	-	-	-	-	13	Major motor events, minor motor events, unresponsiveness, dystonic posturing, subjective experiences, pelvic trusting, back arching, weakness, head turning
Reuber et al. (2002)	74	-	-	95	-	-	-	169	Convulsive components (tonic-clonic-like, tonic-like), flaccid, sensory
Ristić et al. (2015) ^a	37	-	37	-	-	-	-	74	Dialectic-like-loss of consciousness without motor symptoms, atactic-like-loss of consciousness and muscle tone with fall, motor-different phenomenon, and multiple
van der Kruis et al. (2012) ^a	11	-	12	-	-	-	-	23	Major motor events, unresponsiveness
van der Kruis et al. (2014) ^a	21	-	27	-	-	-	-	48	Major motor events, unresponsiveness without motor events
Varma et al. (1996)	10	10	-	-	-	-	-	20	Alterations in consciousness, bilateral motor phenomena

PNES = psychogenic non-epileptic seizures; ES = epilepsy; Psych = psychiatric disorder; IED = interictal epileptiform discharges.

^a Indicates studies included in meta-analysis.

Table 2
Results of the rating system.

Study	Video- EEG confirmed	Matched controls	Epilepsy excluded	Psych excluded	Other CNS excluded	Other FND excluded	Medication accounted for	Imaging acquisition & analysis	Sample size	Score out of 1	Overall rating
Arthuis et al. (2015)	Yes	Yes	Yes	Yes	Yes	No	No	Yes	Moderate	0.7	Moderate
Bolen et al. (2016)	Yes	No	Yes	No	N/A	No	No	Yes	Good	0.6	Moderate
Devinsky et al. (2001)	Yes	No	Yes	No	N/A	No	No	No	Good	0.5	Moderate
Ding et al. (2013)	Yes	No	Yes	Yes	Yes	No	Yes	Yes	Moderate	0.7	Moderate
Ding et al. (2014)	Yes	No	Yes	Yes	Yes	No	Yes	Yes	Moderate	0.7	Moderate
Etkinger et al. (1998)	Yes	No	Yes	No	No	No	Yes	Yes	Poor	0.4	Poor
Hernando et al. (2015)	Yes	Yes	Yes	No	No	No	No	Yes	Poor	0.4	Poor
Labate et al. (2012)	Yes	Yes	Yes	No	Yes	No	Yes	Yes	Moderate	0.7	Moderate
Lee et al. (2015)	Yes	Yes	Yes	No	Yes	No	No	Yes	Moderate	0.6	Moderate
Li et al. (2014)	Yes	No	Yes	Yes	Yes	No	Yes	Yes	Moderate	0.7	Moderate
Li et al. (2015)	Yes	No	Yes	Yes	Yes	No	Yes	Yes	Moderate	0.7	Moderate
Neiman et al. (2009)	Yes	No	Yes	No	No	No	No	Yes	Poor	0.3	Poor
Reuber et al. (2002)	Yes	No	Yes	No	N/A	No	Yes	Yes	Good	0.7	Moderate
Ristić et al. (2015)	Yes	No	Yes	No	Yes	No	Yes	Yes	Moderate	0.6	Moderate
van der Krujis et al. (2012)	Not all	No	Yes	Yes	Yes	No	Yes	Yes	Poor	0.5	Moderate
van der Krujis et al. (2014)	Not all	No	Yes	Yes	Yes	No	Yes	Yes	Moderate	0.6	Moderate
Varma et al. (1996)	Yes	Yes	Yes	No	Yes	No	No	Yes	Poor	0.5	Moderate

Psych = psychiatric conditions; CNS = central nervous system; FND = functional neurological disorders.

these patients ($n = 79$). Of these, 76% demonstrated unilateral abnormalities ($n = 60$) of which 85% were structural (MRI, CT). When comparing this group of PNES patients to a comparison group with epilepsy without PNES ($n = 102$), Devinsky et al. (2001) found significantly more right-sided abnormalities in the PNES group (71%) compared to the epilepsy group without PNES (46.5%). While Reuber et al. (2002) also found evidence of brain disease in PNES only patients (27%) compared to patients with PNES plus epilepsy (78%), in contrast to Devinsky et al. (2001), Reuber et al. (2002) observed no significant difference in lateralization between PNES only patients and patients with PNES plus epilepsy and both groups showed abnormalities in frontal (PNES only = 5%; PNES plus epilepsy = 18.9%) as well as temporal brain regions (PNES only = 40%; PNES plus epilepsy = 54.1%). A more recent study by Bolen et al. (2016) reported similar prevalence rates, with 33.8% of patients with PNES only compared to 57.7% of patients with epilepsy showing structural brain abnormalities. They also noted significantly more multifocal abnormalities in frontal, temporal, parietal, occipital, cerebellar and brainstem brain regions in the PNES only patients (47.8%) compared to the epilepsy group (21.9%), in which significantly more temporal abnormalities were detected for those with epilepsy only (57.8% vs 21.7%).

While all of the authors of these studies suggest that these findings point to a plausible mechanism through which non-epileptic seizures might occur due to pathological brain changes, all three studies have a number of significant limitations. Firstly, these studies were retrospective, and therefore it is unclear whether the observed brain abnormalities occurred before or after PNES onset and therefore predisposition or consequence cannot be determined. Furthermore, because all three studies lacked healthy control subjects, the authors have to draw on other studies demonstrating that the prevalence of brain abnormalities in the general population is lower than that found in their respective PNES groups and therefore the frequency of markers of physical brain disease for these studies remains unclear. Additionally, all of these studies were undertaken in well characterized but also particularly disabled patient populations at specialist centres. This may have introduced a certain degree of selection bias which may have resulted in a higher prevalence rate of brain abnormalities as measured by MRI or CT than might be expected in the wider PNES patient population.

Secondly, given the high levels of psychiatric comorbidity in patients with PNES (Diprose et al., 2016), it is impossible to infer that these brain abnormalities are specifically associated with this seizure disorder and not with other co-existing psychopathologies. While Bolen et al. (2016) suggest that the significant trend toward multifocal abnormalities in their PNES sample may be directly related to the underlying co-existing psychopathology, this is not clear because instances of concurrent psychopathology was not reported in their sample. In addition, there may also be other psychological reasons why an individual with structural brain abnormalities may develop PNES and this again is unclear. Thirdly, the hypothesis put forward by Devinsky et al. (2001) that the prevalence of right-sided abnormalities might facilitate conversion due to non-dominant hemispheric injury or damage is not supported by either Reuber et al. (2002) nor Bolen et al. (2016). In addition, it is unclear how the emotion dysregulation hypothesis that they put forward for PNES is directly associated with seizure like episodes because emotional processing was not directly measured in their study. Rather, the lack of clear hemispheric dominance or lobar preponderance emanating from these studies supports the notion of a heterogeneous aetiology and phenomenology of PNES.

While the three studies described above observed pathological brain abnormalities in a proportion of patients with PNES, the majority of patients with PNES, on visual inspection, do not appear to show any evidence of brain disease or injury. One way to look for differences at the morphological level not apparent on visual inspection of individual scans, is to use computer-aided analysis of structural brain imaging using T 1-weighted volumetric MRI scans of the brain. This method

Table 3
Neuroimaging studies of PNES and summary of results.

Study	Design	Imaging	Results/brain regions	Limitations
Arthuis et al. (2015)	Retrospective	FDG-PET	PNES hypometabolism in RT IFG/central and bilateral ACC > HCs ($p < 0.001$)	Retrospective, small sample size, PTSD/anxiety not controlled for, did not measure dissociative traits, no psychiatric group
Bolen et al. (2016)	Retrospective	sMRI	PNES increased MF abnormalities > ES ($p < 0.018$); PNES decreased TL abnormalities > ES ($p < 0.003$)	Retrospective, no HCs, no psychiatric controls
Devinsky et al. (2001)	Retrospective	sMRI, CT, EEG	PNES predominance of RT hemisphere abnormalities (85%) > combined epilepsy groups (78%; $p < 0.02$)	Retrospective, no HCs, no account for the effects of anticonvulsants and/or psychiatric medications
Ding et al. (2013)	Case control	rsfMRI, DTI	PNES decreased of coupling strength between FC and SC > HCs ($p < 0.0006$)	Small sample size, no psychiatric group
Ding et al. (2014)	Case control	fMRI	PNES increased SRFC in LT MFG, SFG, ACC, SMA, and bilateral MCC; SRFC decreased in RT MOG > HCs ($p < 0.05$); PNES increased LRFC in bilateral CF, LG, SMA, and RT STG, insula, pre- and post-CG, left PL; PNES decreased LRFC in RT MPFC, MFG, IFG, SFG, SMG, and IPG > HCs ($p < 0.05$)	Small sample size, weak correction for multiple comparisons (AlphaSim program), correlations between illness duration and altered FCD were not corrected for multiple comparisons, no psychiatric group
Eitinger et al. (1998)	Case control	SPECT, interictal, postictal	PNES abnormal SPECT interictal (27%), postictal (27%) all hypoperfusion > ES abnormal SPECT interictal (36%), postictal (64%), 6 hypoperfusion, 1 hyperperfusion; postictal vs interictal SPECT PNES vs ES ($p < 0.12$)	Small sample size, no HCs, psychiatric conditions not controlled for, abnormal sMRI in 2 PNES cases
Hernando et al. (2015)	Case control	DTI	PNES greater No. UF streamlines in RT hemisphere > HCs ($p < 0.021$); UF asymmetry significantly correlated with age at illness onset ($p < 0.0045$)	Small sample size, may have incorporated other fibers associated with other pathways other than UF; did not include all of the UF due to the technical limitations, mostly female sample (87%), 2 different scanners used
Labate et al. (2012)	Case control	sMRI, CTH, VBM	PNES VBM GM reductions in bilateral cerebellum, RT precentral gyrus, MFG, ACC and SMA > HCs ($p < 0.05$); PNES CTH reductions in RT precentral gyrus, SFG, precuneus, PL > HCs ($p < 0.05$)	Small sample size, retrospective, 2 different scanners used, no psychiatric group
Lee et al. (2015)	Retrospective	DTI	PNES increased connectivity LT hemisphere, internal and external capsules, corona radiata, UF and STG > HCs ($p < 0.05$)	Small sample size, no psychiatric group
Li et al. (2014)	Case control	rsfMRI	PNES increased FC between insular subregions and LT SPG, putamen, postcentral gyrus, RT LG and bilateral SMA > HCs ($p < 0.05$)	Small sample size, no psychiatric group
Li et al. (2015)	Case control	rsfMRI	PNES increased fALFF in LT SFG, precuneus, PL, SMA and RT postcentral gyrus and decreased fALFF in LT IFG > HCs ($p < 0.05$); PNES increased FC in precuneus, ACC, MCC, postcentral gyrus, frontal and parietal cortices, and decreased FC in MFG > HCs ($p < 0.05$)	No sig. correlations between fALFF and FC, no psychiatric group
Neiman et al. (2009)	Retrospective	SPECT, SISOM	PNES abnormal SISCOM (15%) in LT insula, RT insula, RT frontal regions, all hyperperfusion	Small sample size, no HCs, retrospective, high levels of psychiatric comorbidity in PNES sample, semiology consistent with partial seizures in 9/13 PNES patients, abnormal sMRI in 5/13 PNES patients, abnormal interictal EEG in 5/13 PNES patients
Reuber et al. (2002)	Retrospective	sMRI, EEG	PNES brain abnormalities (27%) > PNES plus ES (77.9%) ($p < 0.001$); PNES No sig. diff. in lateralization > HCs	Retrospective, no HCs, no psychiatric group
Ristić et al. (2015)	Case control	sMRI, CTH	PNES CTH increases in LT insula, MOF, LOF, and RT MOF > HCs ($p < 0.001$); PNES CTH decreased in RT precentral, entorhinal, LOC and LT precentral gyrus > HCs ($p < 0.001$)	No psychiatric group
van der Krujts et al. (2012)	Case control	rsfMRI, event-related fMRI	PNES increased FC in insular subregions, CS, PCC and ACC, POF > HCs; No sig. diff. for activation patterns to fMRI tasks; PNES increased dissociation scores > HCs ($p < 0.05$)	Small sample size, no psychiatric group
van der Krujts et al. (2014)	Case control	rsfMRI	PNES increased coactivation of OFC, insular and subcallosal cortex in F-P RSN; cingulate and insular cortex in EC RSN; cingulate gyrus, SPL, pre- and post CG and SMA in sensorimotor RSN; precuneus, (para-) cingulate gyri in DMN RSN ($p < 0.05$); PNES decreased coactivation OFC in EC RSN; precuneus in sensorimotor RSN > HCs ($p < 0.05$)	Small sample size, no psychiatric group
Varma et al. (1996)	Case control	SPECT, HMPAO	PNES abnormal SPECT (30%) hypoperfusion in bifrontal, LT F-P, RT middle temporal region > ES abnormal SPECT hypoperfusion (80%)	Small sample size, no HCs, high levels of psychiatric comorbidity in PNES sample

ACC = anterior cingulate cortex; CF = calcarine fissure; CG = central gyrus; CS = central sulcus; CT = computational tomography; CTH = cortical thickness; DMN = default mode network; DTI = diffusion tensor imaging; EC = executive control; EEG = electroencephalography; ES = epilepsy; fALFF = fractional amplitude low-frequency fluctuations; FC = functional connectivity; FDG-PET = fluorodeoxyglucose – positron emission tomography; fMRI = functional magnetic resonance imaging; F-P = fronto-parietal; GM = gray matter; HCs = healthy controls; HMPAO = hexamethyl propylene amine oxime; IFG = inferior frontal gyrus; IPG = inferior parietal gyrus; LG = lingual gyrus; LOC = lateral occipital cortex; LOF = lateral orbitofrontal; LRFC = long range functional connectivity; LT = left; MCC = middle cingulate cortex; MF = multifocal; MFG = middle frontal gyrus; MOF = medial orbitofrontal; MOG = middle occipital gyrus; MPFC = medial prefrontal cortex; OFC = orbitofrontal cortex; PCC = posterior cingulate cortex; PL = paracental lobe; PNES = psychogenic nonepileptic seizures; POF = post-traumatic stress disorder; rsfMRI = resting state functional magnetic resonance imaging; RSN = resting state network; RT = right; SC = structural connectivity; SFG = superior frontal gyrus; SISCOM = subtraction ictal SPECT coregistered to MRI; SMA = supplementary motor area; SMG = superior marginal gyrus; sMRI = structural magnetic resonance imaging; SPECT = single photon emission computed tomography; SPL = superior parietal lobe; SRFC = short range functional connectivity; STG = superior temporal gyrus; STG = superior parietal gyrus; TL = temporal lobe; UF = uncinate fasciculus; VBM = voxel based morphology.

allows for the non-invasive quantification of different anatomical features of the brain in terms of shape, volume and density. In contrast to individual or even group level visual inspection of MRI scans or manual measurement of structures of interest, morphometric brain measurements are largely automated and allow for larger scale un-biased group comparisons.

Two common brain morphometry techniques are voxel based morphometry (VBM) and surface-based morphometry. VBM essentially performs statistical tests on all of the voxels in the T1-weighted MRI image and can be used to measure overall gray matter and white matter volume as well as increases/decreases in cerebral spinal fluid (Ashburner and Friston, 2000; Whitwell, 2009). Surface-based morphometry is a technique in which, once the brain is segmented, the boundary between different classes of tissue can be reconstructed as a surface on which morphometric analysis can proceed, for example cortical thickness, cortical surface area and cortical folding patterns (Fischl and Dale, 2000).

3.2.2. Morphological brain changes in patients with PNES

To date only two morphological studies have examined structural brain changes in individuals with PNES compared to healthy controls. Labate et al. (2012) combined two approaches, VBM and surface-based morphometry. VBM analysis revealed significant gray matter volume reductions in the cerebellum (bilateral), the right precentral gyrus, right middle frontal gyrus, right anterior cingulate cortex, and right supplementary motor area in PNES patients ($n = 20$) compared to age and gender matched healthy controls ($n = 40$). Cortical thickness analysis results revealed cortical thinning in the right precentral gyrus, right superior frontal gyrus, right precuneus and right paracentral gyrus in PNES patients compared to the matched healthy controls. Additional analyses revealed negative correlations between depression scores and atrophy involving the right dorsal premotor cortex, the right paracentral gyrus, the right superior frontal gyrus and right orbitofrontal sulcus thickness, as well as negative correlations between dissociation scores and atrophy in the left inferior frontal gyrus (pars opercularis) and the left central sulcus in patients with PNES.

The findings from a second surface-based morphometric study by Ristić et al. (2015) differ somewhat from those reported by Labate et al. (2012). In this study Ristić et al. (2015) found that compared to healthy controls ($n = 37$), patients with PNES ($n = 37$) showed increases in cortical thickness in the left insula, left and right medial orbitofrontal and left orbitofrontal regions, as well as decreases in cortical thickness in the right precentral gyrus, right entorhinal, right lateral occipital and left precentral areas. In addition, they also noted increased sulcal depth in the left and right insular sulci, right rostral anterior cingulate, right posterior cingulate, and left cuneus, and reduced sulcal depth in the right and left medial orbito-frontal sulci in patients with PNES compared to controls. Correlational analysis between cortical thickness results and clinical features revealed weak to moderate negative correlations between the left insula thickness and disease onset ($r = -0.37$), the left precentral thickness and illness duration ($r = -0.34$), and a weak to moderate positive correlation between the right entorhinal thickness and disease onset ($r = 0.37$). However, no other significant correlations were found for history of abuse, a stressful event identified as a trigger, seizure frequency, semiology, or number of antiepileptic drugs (AEDs) taken.

While both studies report cortical thickness decreases in patients with PNES, the results of these two studies also differ, with one reporting cortical thickness decreases only in the right hemisphere (Labate et al., 2012) and the other reporting bilateral cortical thickness decreases as well as cortical thickness increases in limbic and orbitofrontal regions (Ristić et al., 2015). While this may reflect differences in patient selection and sample size, differences between the two sets of results may be best interpreted as again reflecting the heterogeneous nature of this condition. Moreover, while both studies suggest that there is an association between emotion dysregulation linked to

dissociative experiences (Ristić et al., 2015), or “psychogenic causation” due to trauma (Labate et al., 2012), this is not scientifically valid as neither study used other physiological or self-report measures to assess emotion regulatory abilities. Moreover, changes in brain morphometry may also occur for reasons other than pathology (Draganski et al., 2006; Zatorre et al., 2012).

3.2.3. Structural connectivity in patients with PNES – diffusion tensor imaging

Another way to look at structural brain changes more closely associated with brain function is by looking at the strength and integrity of connections between different parts of the brain (how the brain is wired). One technique that has revolutionized our ability to examine structural connectivity between different brain regions is diffusion tensor imaging (DTI). DTI is an in vivo non-invasive technique used to examine cerebral white matter fibre bundles or tracts that facilitate inter-regional neural communication.

Hernando et al. (2015) used DTI indices including fractional anisotropy and diffusion tensor tractography to examine the white matter structural connectivity of the uncinate fasciculus in PNES patients ($n = 8$) and age and gender matched healthy controls ($n = 8$). The uncinate fasciculus is a prominent tract for connecting medial prefrontal regions with limbic areas which include the amygdala and hippocampus (Ebeling and Cramon, 1992; Seminowicz et al., 2004), which play key roles in emotion and memory processes (Schmahmann et al., 2008). They found a significantly greater number of uncinate fasciculus streamlines (visual and statistical representation of white matter tracts) in the right hemisphere when compared to the left hemisphere in patients with PNES and these differences were not evident in the healthy controls. This pattern of connectivity suggests that individuals with PNES may have a stronger connection between prefrontal regions and limbic regions in the right hemisphere compared to the left hemisphere, and like Devinsky et al. (2001), Hernando et al. (2015) suggest that this rightward asymmetry may have detrimental effects on emotion regulation. However, another DTI study by Lee et al. (2015) using fractional anisotropy (FA) and mean diffusivity to measure differences in white matter tracts in the whole-brain between PNES patients ($n = 16$) and age and gender matched healthy controls ($n = 16$) found increased connectivity in the uncinate fasciculus and superior temporal gyrus in the left hemispheric areas, not the right, in addition to the corona radiata and internal and external capsule associated with motor function. Notably, the authors found no significant differences between average FA in regions with increased FA and clinical measures including event frequency and duration of illness.

Taken together, these findings are again somewhat contradictory with one study reporting right hemisphere differences (Hernando et al., 2015) and the other left hemisphere differences between PNES patients and healthy controls (Lee et al., 2015). While both DTI studies propose that non-epileptic seizures may be associated with changes or abnormalities in white matter tracts such as the uncinate fasciculus, and that greater structural connectivity between prefrontal regions and limbic regions may predispose individuals to PNES through emotion dysregulation, this conclusion is highly overstated as neither study empirically tested this hypothesis. Additionally, it is not clear from either study how such a hypothesis easily translates to brain function in so far as it could be argued that greater connectivity of the uncinate fasciculus may in fact strengthen the ability to downregulate emotional responses rather than cause emotion dysregulation. Furthermore, given the complexity of structural connectivity of white matter and the vast number of subcortical brain connections, it is very possible that other fibre tracts involved in other pathways and therefore function were also included, an important limitation recognised by both study reports.

In summary, while all of the structural MRI studies reviewed in this section lend support for the view that structural brain changes may be present in patients with PNES, a number of limitations are also evident in addition to the heterogeneity of the results. Therefore, these results

may be incidental and related to a third factor independently associated with PNES, such as a history of trauma, neglect in early life or concurrent psychopathology. Future studies should better attempt to account for these confounds by describing psychopathology in greater detail alongside personal history and personality characteristics so that the effects of different manifestations of psychopathology can be better aligned to the imaging results. It would also be helpful if future studies recruited control groups with certain types of psychopathology or different levels of trauma exposure. This necessarily implies that future studies will need to be much larger so that clinically different sub-populations do not have to be analysed together which may cancel out significant findings.

3.3. Brain activation patterns and resting state networks in patients with PNES

In the previous section it was hypothesised that structural brain changes may have adverse effects on brain function, potentially contributing to phenomena such as seizure like episodes. One way to investigate links between brain function and PNES is to use imaging modalities which assess real time functional brain activity in individuals with non-epileptic seizures.

3.3.1. Positron emission tomography

Arthuis et al. (2015) used interictal ^{18}F FDG - PET to examine resting state brain metabolic alterations in PNES patients. ^{18}F FDG or fludeoxyglucose F 18 is a radiopharmaceutical used in PET to assess tissue uptake of glucose, and can provide an indirect measure of brain metabolic function/activation. Compared to healthy controls ($n = 16$), PNES patients ($n = 16$) showed significant hypometabolism (lower glucose uptake) in two specific brain areas, namely the right inferior parietal/central brain region and bilateral anterior cingulate. No significant differences in hypermetabolism were observed in patients with PNES compared to healthy controls. The authors further examined how metabolic activity in these two clusters was associated with metabolic activity across the whole brain in both PNES patients and healthy controls. Compared to healthy controls, PNES patients showed significant correlations in metabolic activity between the right inferior parietal/central brain region and bilateral cerebellum and between bilateral anterior cingulate and the left hippocampal gyrus. However, the authors did not find any significant correlations between the metabolic activities of the clusters reported clinical features in the PNES group (age, age at onset, frequency, duration or semiology).

From their results Arthuis et al. (2015) concluded that interictal resting state metabolic brain changes in PNES may reflect disturbances in brain function. The authors suggest that these disturbances may relate to two distinct pathophysiological mechanisms involved in PNES, namely emotion dysregulation (bilateral anterior cingulate hypometabolism) and dysfunctional processes associated with self-awareness/consciousness of one self and the environment (right inferior parietal hypometabolism). However, as the authors point out, these findings need to be interpreted with a certain degree of caution. This is because parameters relating to dissociative traits, emotion processing and certain psychiatric comorbidities such as anxiety, depression and PTSD were not formally assessed. Thus, co-existing psychopathology may have had a significant effect on the results, especially given that the anterior cingulate cortex has been implicated in both anxiety and PTSD (Bishop et al., 2004; Shin et al., 2001). Additionally, it is difficult to interpret the association between metabolic activity in the right inferior parietal/central brain region and bilateral cerebellum, and between bilateral anterior cingulate and the left hippocampal gyrus. The significance of these findings is unclear. Moreover, the lack of any significant findings relating to metabolic activity in the brain and clinical features of PNES could suggest that these brain changes observed are not related to PNES. However, there is also a strong possibility that the imaging method employed in this study, and this generalizes to other

neuroimaging methodologies, may not be sensitive enough to correctly identify associations between brain activity and symptomatology.

3.3.2. Single photon emission computed tomography

Another unique and potentially informative approach to examining potential brain abnormalities in PNES is single photon emission computed tomography (SPECT). This imaging modality integrates two technologies, computed tomography (CT), and the use a radioactive tracer injected into the patient before the scan. SPECT differs from a PET scan in that the tracer stays in the blood stream rather than being absorbed by surrounding tissues, thereby limiting the images to areas where blood flows in the brain. During seizures, regional cerebral flow may increase at the brain site of epileptic origin (hyperperfusion) while interictally, the epileptic focus may demonstrate decreases in regional cerebral blood flow (hypoperfusion) (Devous et al., 1998). This procedure facilitates the localization of the epileptic focus of the seizures themselves when seizure brain activity is present but remains undetectable by scalp-recorded EEG.

To date SPECT has been solely used in difficult cases involving complex medical histories suggestive of both PNES and epilepsy in which differential diagnosis remains questionable. In such cases, SPECT has proven useful in differentiating epileptic from non-epileptic episodes by using computer-aided quantification of ictal, inter-ictal and postictal changes in regional cerebral blood flow (Ettinger et al., 1998; Nieman et al., 2009; Varma et al., 1996). The use of SPECT in PNES is important because it supports the proposition that PNES is indeed different from epilepsy in the majority of PNES cases. However, like structural MRI studies which have observed instances of brain disease or injury in a sub-population of PNES patients ranging from 25% to 34% (Bolen et al., 2016; Devinsky et al., 2001; Reuber et al., 2002), the SPECT studies outlined below have observed similar prevalence rates of abnormal regional cerebral blood flow in a subset of patients with confirmed PNES diagnosis (range 15%–30%).

An early study to utilize SPECT in patients with PNES was conducted by Varma et al. (1996). In this study they observed abnormal SPECT results in 30% of patients with PNES only ($n = 3/10$; bifrontal, left frontoparietal, right medial temporal hypoperfusion) compared to 80% of age and gender matched epilepsy patients, who demonstrated clear focal hypoperfusion suggestive of epileptogenic origin ($n = 8/10$). In line with these findings, Ettinger et al. (1998) observed abnormal postictal SPECT scan results in 27% of patients who experienced non-epileptic seizures ($n = 3/11$; all hypoperfusion) compared to 64% of patients with epileptic episodes ($n = 7/11$; hypoperfusion in six, hyperperfusion in one). Consistent with Varma et al. (1996) and Ettinger et al. (1998), a more recent SPECT study by Neiman et al. (2009), this time using subtraction ictal SPECT coregistered to MRI (SISCOM), observed abnormal SISCOM results in 15% of patients with non-epileptic seizures ($n = 2/13$; right posterolateral frontal and right insular hyperperfusion).

In the majority of cases, SPECT studies support the differential diagnosis of PNES based on the absence of a clear epileptogenic origin in the brain. Nonetheless, observed brain abnormalities in regional cerebral blood flow appear to be present in a minority of PNES cases. This suggests that, to date, our understanding of this disorder as purely psychogenic may need to be reconsidered and the use of PNES as an umbrella term/diagnosis fails to appropriately classify PNES sub-populations. However, these findings are difficult to interpret given the small sample size, the use of a highly selective PNES sub-population, and the absence of age and gender matched healthy controls. Additionally, abnormal SPECT scans reported for a certain percentage of PNES patients may also result from having other nonpsychogenic conditions such as brain disease or injury, cardiovascular disease and/or other psychiatric comorbid conditions (Camargo, 2001). All of the above again emphasises the importance of the clinical context in which diagnosis, treatment, and studies involving individuals with PNES are conducted.

3.3.3. Functional magnetic resonance imaging

Another way to look at brain activity is to use functional magnetic resonance imaging (fMRI). fMRI can be used to measure fluctuations in the blood oxygenation level-dependent signal or BOLD, which is an indirect correlate of neural activity. In addition, resting state functional magnetic resonance imaging (rsfMRI) can be used to measure the same BOLD signal during rest. During rest, co-activation patterns in different brain regions can be used to assess functional connectivity patterns in resting state networks (Van Den Heuvel and Pol, 2010). An important point to note here is that four of the six fMRI studies reviewed in this section come from the same research group and have used the same participants in their analysis (Ding et al., 2013; Ding et al., 2014; Li et al., 2014; Li et al., 2015).

To date, there is only one study that simultaneously investigated structural and functional connectivity in patients with PNES using rsfMRI and DTI. In this study Ding et al. (2013) found that PNES patients ($n = 17$) compared to healthy controls ($n = 20$) demonstrated significant decreases in the strength of both structural connections and functional connectivity in brain regions associated with attention, sensorimotor, and the default mode network. Moreover, the coupling strength of structural-functional connectivity was decreased in patients with PNES and this showed high sensitivity (75%) and specificity (77%) in differentiating PNES patients from healthy controls. Building on this work, Ding et al. (2014) used functional connectivity density mapping based on the same rsfMRI data to assess whether a more detailed examination of both long-range and short-range functional connectivity would differentiate PNES patients ($n = 18$) from healthy controls ($n = 20$). Compared to healthy controls, Ding et al. (2014) found that PNES patients demonstrated bilateral differences in both long-range and short-range functional connectivity mainly in frontal, sensorimotor, cingulate, insular and occipital brain regions. Interestingly, three regions with increased long-range functional connectivity values correlated positively with illness duration, namely the right calcarine fissure ($r = 0.64$), the left lingual gyrus ($r = 0.63$) and the right lingual gyrus ($r = 0.66$).

Again, using the same rsfMRI data as Ding et al. (2013, 2014) but this time focusing on the distinct functional connectivity patterns of insular subregions (Cauda et al., 2011; Craig, 2009; Deen et al., 2011; Kurth et al., 2010b), Li et al. (2014) found that functional connectivity maps based on the left ventral anterior insula (vAI), the right dorsal anterior insula (dAI) and the right posterior insula (PI) showed significant group differences in connectivity values between PNES patients and healthy controls. Both right dAI and PI showed stronger functional connectivity values with the left superior parietal gyrus and left putamen in patients with PNES compared to healthy controls. In addition, the left vAI showed stronger functional connectivity with the right lingual gyrus, left postcentral gyrus and bilateral supplementary motor area (SMA). Also, based on the left vAI seed, functional connectivity values of the left and right SMA were positively correlated with frequency of PNES (SMA_left, $r = 0.59$, SMA_right, $r = 0.60$).

A second follow up study by Li et al. (2015) using the same rsfMRI data, this time using a combination of fractional amplitude low-frequency fluctuations (fALFF; the measurement of spontaneous fluctuations in the BOLD-fMRI regional signal intensity) and functional connectivity values, found that PNES patients compared to healthy controls showed increased synchronous regional activity mainly in the dorso-lateral prefrontal cortex (DLPFC), parietal, and motor regions, and decreased regional activity in the right triangular inferior frontal gyrus which is part of the ventrolateral prefrontal cortex linked, amongst other things, to response inhibition (Aron and Poldrack, 2006). Moreover, PNES patients also showed increased functional connectivity between the DLPFC, sensorimotor and limbic regions and decreased functional connectivity in the ventrolateral prefrontal cortex. Correlational analysis revealed that functional connectivity values between the SMA and the anterior cingulate cortex positively correlated with the frequency of PNES episodes ($r = 0.58$).

The findings from these four studies suggest that alterations in functional connectivity in brain regions associated with attention and regulatory processes, memory, emotion processing and sensory and motor function may be compromised in patients with PNES. These alterations imply less effective communication between different parts of the brain and therefore disruption in information processing, possibly resulting from life experiences, leading to aberrant sensori-motor interactions beyond the conscious control of the individual. Moreover, the inability to down regulate behavioural responses to emotional stimuli (Li et al., 2015) may result from hyper-connectivity between insular subregions and sensori-motor, parietal and occipital brain regions (Li et al., 2014), which may result in a form of maladaptive long-term hypervigilance to external stimuli (Ding et al., 2014). This suggests that alterations in cognitive-emotional-behavioural brain mechanisms may result from adverse life experiences and/or experiential learning leading to PNES (Devinsky et al., 2001; Li et al., 2015; Brown and Reuber, 2016b).

Partially supporting the findings by Ding et al. (2013) and Li et al. (2015), a study by van der Kruis et al. (2014) found that, compared to healthy controls ($n = 27$), PNES patients ($n = 21$) showed increased functional connectivity in resting state networks associated with fronto-parietal activation, executive control, sensorimotor functions, and the default mode. The default mode network is of particular interest as it has been associated with self-awareness/sense of agency and consciousness (Gusnard et al., 2001; Schneider et al., 2008) which may be directly linked to the tendency to dissociate and the expression of motor symptoms occurring as involuntary movements observed in PNES. Moreover, the connectivity strength in resting state networks that showed differences in activation between PNES patients and healthy controls (fronto-parietal, default mode, executive control, and sensorimotor network) were positively correlated with dissociation scores, further implicating the role of these networks in PNES, and lending support to the view that PNES are a manifestation of dissociation (Nijenhuis and Van der Hart, 2011). However, the extrapolation of resting state results to hypothesised activation patterns in response to external stimuli or events is questionable. That is, do individuals with PNES respond differently to external stimuli compared to healthy individuals and can this be measured inside the scanner. To date only one fMRI study has examined brain activation patterns to external stimuli in patients with PNES.

In this study, van der Kruis et al. (2012) conducted four fMRI scans during one scanning session (two resting state scans, one event-related picture-encoding task scan, and one event-related stroop paradigm scan) in patients with PNES ($n = 11$) and healthy controls ($n = 12$). While whole-brain analysis revealed no differences in either task-related fMRI paradigm between PNES patients and healthy controls, functional connectivity maps based on the rsfMRI scans showed significantly stronger functional connectivity patterns in PNES patients compared to controls in areas involved in emotion (insula), executive control and sensory information processing (inferior frontal gyrus and parietal cortex) and movement (precentral sulcus). In addition, functional connectivity values based on the average of both rsfMRI scans showed a significant positive correlation between the precentral sulcus-posterior insula and reported dissociation scores (Spearman's $r_s = 0.56$). Moreover, linear regression analysis with functional connectivity values of the precentral sulcus-posterior insula connection as the dependent variable and dissociation scores as the independent variable, showed that dissociation scores was a significant predictor of the functional connectivity of these two brain regions ($\beta = 0.066$, $p = 0.04$). The authors suggest that a higher tendency to dissociate in PNES, may reflect a vulnerability or predisposition to PNES, whereby the hyper-connectivity between brain regions involved in emotion processing (insula) and motor function (precentral sulcus) goes unchecked by frontal brain regions involved in inhibitory control, resulting in non-epileptic seizure like episodes. These findings are important because they tentatively propose an underlying physical PNES

Table 4
ALE cluster-analysis results for structural studies ($N = 3$).

Cluster	Size/volume mm ³	Weighted centre	Brain areas within ± 5 mm ³	Max. ALE value	x, y, z of max. ALE	Contributors to cluster 1	Studies included
1	424	X = -35.3 Y = -4.6 Z = -9.3	BA 21: left cerebrum/temporal lobe	0.0143	-36, -4, -10	Lee et al. (2015), Ristić et al., 2015).	Labate et al. (2012), Lee et al. (2015), Ristić et al. (2015).
	200		<i>Nearest gray within ± 5mm³</i> Left cerebrum/sub-lobar/claustrium gray matter				
	168		Left cerebrum/temporal lobe/sub-gyral gray matter: BA21				
	48		Left cerebrum/limbic lobe/parahippocampal gyrus and amygdala gray matter				
	8		Left cerebrum/sub-lobar/insula gray matter: BA 13				

Brodman Area (BA), X, Y, Z coordinates in Talairach space.

substrate in the brain for dissociation, which has significant implications for how we view PNES (van der Kruijs et al., 2012).

All of the fMRI studies reviewed in this section provide plausible explanations for associations between fMRI findings and non-epileptic seizures, but there are a significant number of limitations. First and foremost, again these fMRI studies cannot infer any causal relationship between the brain imaging results and PNES. This again leaves open the possibility that these findings may also be incidental, or that they may be related to other factors not under investigation. Furthermore, given that a single brain region may be involved in many different mental processes, it is not clear from the functional studies presented here, that activation patterns involving specific brain regions are solely associated with specific mental processes such as emotion regulation or dissociation, hypothesised to precipitate and perpetuate PNES symptomatology. Moreover, these behaviours have been characterized as paroxysmal rather than chronic and therefore, alterations in the interictal resting state networks may not necessarily be indicative of changes in brain activation patterns during an actual seizure like episode. Another possible confound of these studies relates to whether patients with PNES are engaging the same mental processes as healthy controls while in the scanner. This is arguably unlikely given that PNES patients often have other conditions such as PTSD, depression and anxiety.

Therefore, a certain degree of reverse inference (Aguirre et al., 2003; Poldrack, 2006) may have led to premature conclusions. One could further speculate that because these studies are not longitudinal, a single scan at a single time point cannot tell us if the observed activation patterns reflect state or trait properties. A recent longitudinal study investigating brain function and a broad range of psychological and biological variables in a single human, has in fact demonstrated that brain function has temporal qualities related to both psychological and biological variability and that sensory, motor, and attentional networks actually showed the greatest variability across multiple fMRI sessions (Poldrack et al., 2015). Therefore, future studies in this area should attempt to control for this by scanning individuals with PNES at multiple stages of their disorder.

Moreover, if brain changes are responsible for the aetiology and maintenance of PNES, it is important to know how they relate to clinical features associated with the non-epileptic patients. Again, it is difficult to see clear agreement on the relationship between the imaging results and clinical features. More importantly, self-report measures (including seizure frequency and symptoms) may not be that reliable, especially if they are applied cross-sectionally. It may be more meaningful if the patient reports on the frequency of events or the types of symptoms experienced at several different time points. Furthermore, the relationship between objective measures and self-report measures is poor in many areas of psychopathology. Therefore, it may be advisable to look for correlations between the imaging data and other objective measures such as neuroendocrine measures, heart rate variability changes, EEG, and/or epigenetic data. This may allow us to better understand the relationship between fMRI results and functional

connectivity patterns in patients with PNES.

3.4. Meta-analysis

Given the heterogeneity of results summarised in the preceding sections, we were keen to explore whether any convergent findings could be extracted from the imaging studies carried out in patients with PNES. To that end, we carried out three different ALE meta-analyses using GingerAle (version 2.3.6).

The first meta-analysis included all nine functional and structural studies for which MNI or Talairach coordinates were available and included 307 subjects (Arthuis et al., 2015; Ding et al., 2014; Labate et al., 2012; Lee et al., 2015; Li et al., 2014, 2015; Ristić et al., 2015; van der Kruijs et al., 2012, 2014). This analysis resulted in no significant clusters. The second meta-analysis which focused on all of the functional connectivity studies in PNES patients included six studies with a total of 141 subjects (Arthuis et al., 2015; Ding et al., 2014; Li et al., 2014, 2015; van der Kruijs et al., 2012, 2014). Again, this analysis resulted in no significant clusters. However, the third and final meta-analysis which focused on three imaging studies reporting structural brain differences between PNES patients and controls (Labate et al., 2012; Lee et al., 2015; Ristić et al., 2015) yielded significant findings. This meta-analysis included 166 subjects and resulted in 26 foci. This cluster-level analysis resulted in one significant cluster above the chosen minimum cluster size of 424 mm³ in the left temporal lobe region (Brodman area 21). Table 4 outlines the results of this ALE meta-analysis showing brain areas within ± 5 mm³ of this significant cluster above the corrected p value threshold. Fig. 2 depicts the results of the ALE meta-analysis conducted on the sMRI studies only, showing an overlay of this significant cluster, at the left temporal lobe, superimposed on the high-resolution standard anatomical brain image provided by brainmap.org (Colin_t1rc.nii).

A link between a common abnormality in the temporal lobe and patients with PNES would be in keeping with the results of the studies by Bolen et al. (2016) and Reuber et al. (2002) which identified higher prevalence rates of pathological brain abnormalities in this part of the brain (22% and 40% respectively). However, it is notable that this analysis was only based on three studies, and it is important to take account of the fact that no other convergent brain areas were found when we examined all of the nine studies together or when we examined six studies reporting functional connectivity patterns in PNES patients compared to controls. Considering the small sizes of the studies, the lack of high quality methodological approaches and the dearth of convergent findings, this may indicate that at least some of the studies report chance findings which may not be replicable in larger studies. However, the varied results may also reflect the true aetiological and phenomenological heterogeneity of patients with PNES, pointing to individualized phenotypes and patterns of abnormal brain activation, possibly resulting from individual differences and thus group differences in genetic makeup, anatomical variation, medical history, life

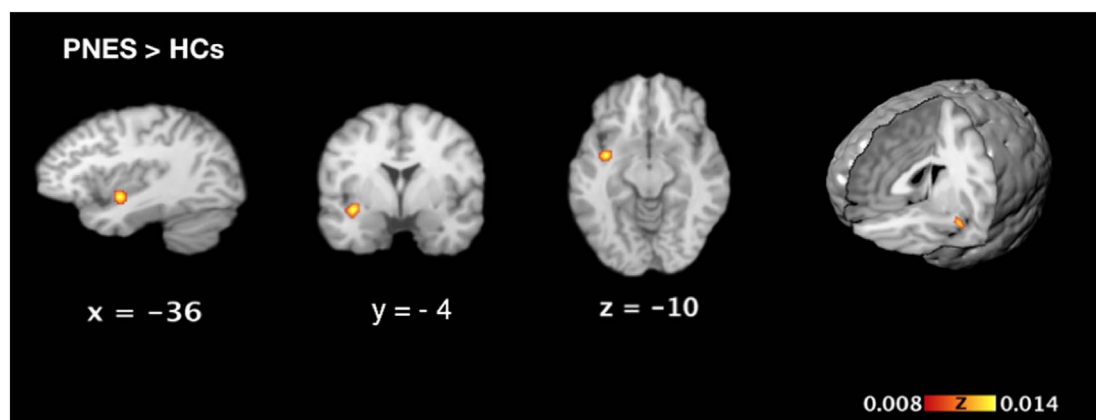


Fig. 2. Activation likelihood estimation (ALE) significance maps based on sMRI studies comparing PNES patients to healthy controls. The only area showing a significant cluster to survive the cluster forming threshold with an uncorrected p -value of 0.001 was found in the left temporal lobe only. Numbers represent the sagittal (x), coronal (y), and axial (z) coordinates of each slice in Talairach space. Scale bar shows z -scores of ALE statistics with increasing significance from left to right. PNES = Psychogenic non-epileptic seizures; HCs = Healthy controls.

experiences, semiology and state and trait characteristics.

3.5. Limitations

This review has a number of limitations. The first relates to the small number of neuroimaging studies in patients with PNES. Although an extensive literature search was conducted only seventeen empirical studies were included in this review. Secondly, it is difficult to draw direct comparisons between the results due to the different imaging methods used and differences in group characteristics which may have influenced the results. Thirdly, the lack of convergence across nine of the studies included in the combined meta-analysis may reflect the heterogeneity of this patient population compounded by the limitations highlighted above in relation to the lack of serial MRI scans taken at different stages of the disorder.

4. Conclusion

The purpose of this systematic meta-review was to provide an up-to-date synthesis and quantification of both structural and functional neuroimaging studies performed on individuals with PNES. The overarching aim was to present the available evidence in an attempt to assess the strength and limitations of these studies to improve our neurobiological understanding of this condition. Although the results presented here appear inconclusive, they nonetheless provide some evidence for an association between structural and functional brain abnormalities in patients with PNES, which may contribute toward a biopsychosocial account of a condition often described as “medically unexplained”. The identification of such neurobiological correlates does not sit well with the understanding of PNES as a purely “psychological” or “psychogenic” disorder without any discernible “physical” correlates. In addition, given the heterogeneity of patients with this condition, characterizing individuals in a narrowly defined manner based singularly on the expression of seizure like episodes does little to advance our knowledge base and fails to sufficiently account for sub-populations which will need to be considered separately in future neuroimaging studies. Furthermore, clear international consensus about PNES diagnosis and semiology is required if we are to standardise measures that can be used in future neuroimaging studies of PNES. Given that psychiatric comorbidities appear overrepresented in PNES, future studies will need to better address this issue by the use of consecutive recruitment of patients with PNES with or without concurrent psychopathologies and comparing their neuroimaging data to patients with psychiatric conditions free of PNES and age and gender matched healthy controls from similar demographic backgrounds. Future studies will also need to address other limitations highlighted by this review by

adopting multimodal approaches in conjunction with a detailed medical history when dealing with individuals who have PNES. Advances in these areas will allow for a better and more detailed understanding of the neurobiological correlates of this disorder, which may have implications for both diagnosis and better treatment options.

References

- Aguirre, G.K., Feinberg, F.T., Farah, M.J., 2003. Functional imaging in behavioral neurology and cognitive neuropsychology. In: Behavioral neurology and cognitive neuropsychology (2nd ed).
- Allendorfer, J.B., Szaflarski, J.P., 2014. Contributions of fMRI towards our understanding of the response to psychosocial stress in epilepsy and psychogenic nonepileptic seizures. *Epilepsy Behav.* 35, 19–25. <http://dx.doi.org/10.1016/j.yebeh.2014.03.023>.
- American Psychiatric Association, 2013. *DSM 5. American Psychiatric Association.*
- Aron, A.R., Poldrack, R.A., 2006. Cortical and subcortical contributions to stop signal response inhibition: role of the subthalamic nucleus. *J. Neurosci.* 26 (9), 2424–2433. <http://dx.doi.org/10.1523/JNEUROSCI.4682-05.2006>.
- Arthuis, M., Micoulaud-Franchi, J.A., Bartolomei, F., McGonigal, A., Guedj, E., 2015. Resting cortical PET metabolic changes in psychogenic non-epileptic seizures (PNES). *J. Neurol. Neurosurg. Psychiatry* 86 (10), 1106–1112. <http://dx.doi.org/10.1136/jnnp-2014-309390>.
- Asadi-Pooya, A.A., 2015. Neurobiological origin of psychogenic nonepileptic seizures: a review of imaging studies. *Epilepsy Behav.* 52, 256–259. <http://dx.doi.org/10.1016/j.yebeh.2015.09.020>.
- Ashburner, J., Friston, K.J., 2000. Voxel-based morphometry—the methods. *NeuroImage* 11 (6), 805–821. <http://dx.doi.org/10.1006/nimg.2000.0582>.
- Baslet, G., 2011. Psychogenic non-epileptic seizures: a model of their pathogenic mechanism. *Seizure* 20 (1), 1–13. <http://dx.doi.org/10.1016/j.seizure.2010.10.032>.
- Bishop, S., Duncan, J., Brett, M., Lawrence, A.D., 2004. Prefrontal cortical function and anxiety: controlling attention to threat-related stimuli. *Nat. Neurosci.* 7 (2), 184–188. <http://dx.doi.org/10.1038/nn1173>.
- Bolen, R.D., Koontz, E.H., Pritchard, P.B., 2016. Prevalence and distribution of MRI abnormalities in patients with psychogenic nonepileptic events. *Epilepsy Behav.* 59, 73–76. <http://dx.doi.org/10.1016/j.yebeh.2016.02.036>.
- Brown, R.J., Reuber, M., 2016a. Psychological and psychiatric aspects of psychogenic non-epileptic seizures (PNES): a systematic review. *Clin. Psychol. Rev.* 45, 157–182. <http://dx.doi.org/10.1016/j.cpr.2016.01.003>.
- Brown, R.J., Reuber, M., 2016b. Towards an integrative theory of psychogenic non-epileptic seizures (PNES). *Clin. Psychol. Rev.* 47, 55–70. <http://dx.doi.org/10.1016/j.cpr.2016.06.003>.
- Camargo, E.E., 2001. Brain SPECT in neurology and psychiatry. *J. Nucl. Med.* 42 (4), 611–623.
- Cauda, F., D'Agata, F., Sacco, K., Duca, S., Geminiani, G., Vercelli, A., 2011. Functional connectivity of the insula in the resting brain. *NeuroImage* 55 (1), 8–23. <http://dx.doi.org/10.1016/j.neuroimage.2010.11.049>.
- Craig, A.D., 2009. How do you feel—now? The anterior insula and human awareness. *Nat. Rev. Neurosci.* 10 (1). <http://dx.doi.org/10.1038/nrn2555>.
- Deen, B., Pitskel, N.B., Pelphrey, K.A., 2011. Three systems of insular functional connectivity identified with cluster analysis. *Cereb. Cortex* 21 (7), 1498–1506. <http://dx.doi.org/10.1093/cercor/bhq186>.
- Devinsky, O., Mesad, S., Alper, K., 2001. Nondominant hemisphere lesions and conversion nonepileptic seizures. *J. Neuropsychiatry Clin. Neurosci.* 13 (3), 367–373. <http://dx.doi.org/10.1176/appi.neuropsych.13.3.367>.
- Devous Sr., M.D., Thisted, R.A., Morgan, G.F., Leroy, R.F., Rowe, C.C., 1998. SPECT brain imaging in epilepsy: a meta-analysis. *The Journal of Nuclear Medicine* 39 (2), 285.
- Ding, J.R., An, D., Liao, W., Li, J., Wu, G.R., Xu, Q., ... Chen, H., 2013. Altered functional and structural connectivity networks in psychogenic non-epileptic seizures. *PLoS One*

- 8 (5), e63850. <http://dx.doi.org/10.1371/journal.pone.0063850>.
- Ding, J., An, D., Liao, W., Wu, G., Xu, Q., Zhou, D., Chen, H., 2014. Abnormal functional connectivity density in psychogenic non-epileptic seizures. *Epilepsy Res.* 108 (7), 1184–1194. <http://dx.doi.org/10.1016/j.eplepsyres.2014.05.006>.
- Diprose, W., Sundram, F., Menkes, D.B., 2016. Psychiatric comorbidity in psychogenic nonepileptic seizures compared with epilepsy. *Epilepsy Behav.* 56, 123–130. <http://dx.doi.org/10.1016/j.yebeh.2015.12.037>.
- Draganski, B., Gaser, C., Kempermann, G., Kuhn, H.G., Winkler, J., Büchel, C., May, A., 2006. Temporal and spatial dynamics of brain structure changes during extensive learning. *J. Neurosci.* 26 (23), 6314–6317. <http://dx.doi.org/10.1523/JNEUROSCI.4628-05.2006>.
- Ebeling, U., Cramon, D.V., 1992. Topography of the uncinate fascicle and adjacent temporal fiber tracts. *Acta Neurochir.* 115 (3), 143–148. <http://dx.doi.org/10.1007/BF01406373>.
- Eickhoff, S.B., 2014. *Brainmap.org*.
- Eickhoff, S.B., Laird, A.R., Grefkes, C., Wang, L.E., Zilles, K., Fox, P.T., 2009. Coordinate-based activation likelihood estimation meta-analysis of neuroimaging data: a random-effects approach based on empirical estimates of spatial uncertainty. *Hum. Brain Mapp.* 30 (9), 2907–2926. <http://dx.doi.org/10.1002/hbm.20718>.
- Eickhoff, S.B., Bzdok, D., Laird, A.R., Kurth, F., Fox, P.T., 2012. Activation likelihood estimation meta-analysis revisited. *NeuroImage* 59 (3), 2349–2361. <http://dx.doi.org/10.1016/j.neuroimage.2011.09.017>.
- Ettinger, A.B., Coyle, P.K., Jandorf, L., Cabahug, C.J., Oster, Z.H., Atkins, H.L., ... Devinsky, O., 1998. Postictal SPECT in epileptic versus nonepileptic seizures. *J. Epilepsy* 11 (2), 67–73. [http://dx.doi.org/10.1016/S0896-6974\(97\)00112-6](http://dx.doi.org/10.1016/S0896-6974(97)00112-6).
- Fischl, B., Dale, A.M., 2000. Measuring the thickness of the human cerebral cortex from magnetic resonance images. *Proc. Natl. Acad. Sci.* 97 (20), 11050–11055. <http://dx.doi.org/10.1073/pnas.200033797>.
- Green, A., Payne, S., Barnitt, R., 2004. Illness representations among people with non-epileptic seizures attending a neuropsychiatry clinic: a qualitative study based on the self-regulation model. *Seizure* 13 (5), 331–339. <http://dx.doi.org/10.1016/j.seizure.2003.09.001>.
- Gusnard, D.A., Akbudak, E., Shulman, G.L., Raichle, M.E., 2001. Medial prefrontal cortex and self-referential mental activity: relation to a default mode of brain function. *Proc. Natl. Acad. Sci.* 98 (7), 4259–4264. <http://dx.doi.org/10.1073/pnas.071043098>.
- Hernando, K.A., Szafarski, J.P., Ver Hoef, L.W., Lee, S., Allendorfer, J.B., 2015. Uncinate fasciculus connectivity in patients with psychogenic nonepileptic seizures: a preliminary diffusion tensor tractography study. *Epilepsy Behav.* 45, 68–73. <http://dx.doi.org/10.1016/j.yebeh.2015.02.022>.
- Katzman, G.L., Dagher, A.P., Patronas, N.J., 1999. Incidental findings on brain magnetic resonance imaging from 1000 asymptomatic volunteers. *JAMA* 282 (1), 36–39. <http://dx.doi.org/10.1001/jama.282.1.36>.
- van der Kruijs, S.J., Bodde, N.M., Vaessen, M.J., Lazeron, R.H., Vonck, K., Boon, P., ... Jansen, J.F., 2012. Functional connectivity of dissociation in patients with psychogenic non-epileptic seizures. *J. Neurol. Neurosurg. Psychiatry* 83, 239–247. <http://dx.doi.org/10.1136/jnnp-2011-300776>.
- van der Kruijs, S.J., Jagannathan, S.R., Bodde, N.M., Besseling, R.M., Lazeron, R.H., Vonck, K.E., ... Aldenkamp, A.P., 2014. Resting-state networks and dissociation in psychogenic non-epileptic seizures. *J. Psychiatr. Res.* 54, 126–133. <http://dx.doi.org/10.1016/j.jpsychires.2014.03.010>.
- Kurth, F., Zilles, K., Fox, P.T., Laird, A.R., Eickhoff, S.B., 2010. A link between the systems: functional differentiation and integration within the human insula revealed by meta-analysis. *Brain Struct. Funct.* 214 (5–6), 519–534. <http://dx.doi.org/10.1007/s00429-010-0255-z>.
- Labate, A., Cerasa, A., Mula, M., Mumoli, L., Gioia, M.C., Aguglia, U., ... Gambardella, A., 2012. Neuroanatomic correlates of psychogenic nonepileptic seizures: a cortical thickness and VBM study. *Epilepsia* 53 (2), 377–385. <http://dx.doi.org/10.1111/j.1528-1167.2011.03347.x>.
- LaFrance, W.C., Reuber, M., Goldstein, L.H., 2013. Management of psychogenic nonepileptic seizures. *Epilepsia* 54 (s1), 53–67. <http://dx.doi.org/10.1111/epi.12106>.
- Laird, A.R., Robinson, J.L., McMillan, K.M., Tordesillas-Gutiérrez, D., Moran, S.T., Gonzales, S.M., ... Lancaster, J.L., 2010. Comparison of the disparity between Talairach and MNI coordinates in functional neuroimaging data: validation of the Lancaster transform. *NeuroImage* 51 (2), 677–683. <http://dx.doi.org/10.1016/j.neuroimage.2010.02.048>.
- Lancaster, J.L., Tordesillas-Gutiérrez, D., Martínez, M., Salinas, F., Evans, A., Zilles, K., ... Fox, P.T., 2007. Bias between MNI and Talairach coordinates analyzed using the ICBM-152 brain template. *Hum. Brain Mapp.* 28 (11), 1194–1205. <http://dx.doi.org/10.1002/hbm.20345>.
- Lee, S., Allendorfer, J.B., Gaston, T.E., Griffis, J.C., Hernando, K.A., Knowlton, R.C., ... Ver Hoef, L.W., 2015. White matter diffusion abnormalities in patients with psychogenic non-epileptic seizures. *Brain Res.* 1620, 169–176. <http://dx.doi.org/10.1016/j.brainres.2015.04.050>.
- Li, R., Liu, K., Ma, X., Li, Z., Duan, X., An, D., ... Chen, H., 2014. Altered functional connectivity patterns of the insular subregions in psychogenic nonepileptic seizures. *Brain Topogr.* 28 (4), 636–645. <http://dx.doi.org/10.1007/s10548-014-0413-3>.
- Li, R., Li, Y., An, D., Gong, Q., Zhou, D., Chen, H., 2015. Altered regional activity and inter-regional functional connectivity in psychogenic non-epileptic seizures. *Sci Rep* 5. <http://dx.doi.org/10.1038/srep11635>.
- Neiman, E.S., Noe, K.H., Drazkowski, J.F., Sirven, J.I., Roarke, M.C., 2009. Utility of subtraction ictal SPECT when video-EEG fails to distinguish atypical psychogenic and epileptic seizures. *Epilepsy Behav.* 15 (2), 208–212. <http://dx.doi.org/10.1016/j.yebeh.2009.02.042>.
- Nijenhuis, E.R., Van der Hart, O., 2011. Dissociation in trauma: a new definition and comparison with previous formulations. *J. Trauma Dissociation* 12 (4), 416–445. <http://dx.doi.org/10.1080/15299732.2011.570592>.
- Perez, D.L., Dworetzky, B.A., Dickerson, B.C., Leung, L., Cohn, R., Baslet, G., Silbersweig, D.A., 2015. An integrative neurocircuit perspective on psychogenic nonepileptic seizures and functional movement disorders neural functional unawareness. *Clin. EEG Neurosci.* 46 (1), 4–15. <http://dx.doi.org/10.1177/1550059414555905>.
- Poldrack, R.A., 2006. Can cognitive processes be inferred from neuroimaging data? *Trends Cogn. Sci.* 10 (2), 59–63. <http://dx.doi.org/10.1016/j.tics.2005.12.004>.
- Poldrack, R.A., Laumann, T.O., Koyejo, O., Gregory, B., Hoyer, A., Chen, M.Y., ... Hunnicke-Smith, S., 2015. Long-term neural and physiological phenotyping of a single human. *Nat. Commun.* 6. <http://dx.doi.org/10.1038/ncomms9885>.
- Rawlings, G.H., Reuber, M., 2016. What patients say about living with psychogenic nonepileptic seizures: a systematic synthesis of qualitative studies. *Seizure* 41, 100–111. <http://dx.doi.org/10.1016/j.seizure.2016.07.014>.
- Reuber, M., 2009. The etiology of psychogenic non-epileptic seizures: toward a biopsychosocial model. *Neurol. Clin.* 27 (4), 909–924. <http://dx.doi.org/10.1016/j.ncl.2009.06.004>.
- Reuber, M., Fernandez, G., Helmstaedter, C., Qurishi, A., Elger, C.E., 2002. Evidence of brain abnormality in patients with psychogenic nonepileptic seizures. *Epilepsy Behav.* 3 (3), 249–254. [http://dx.doi.org/10.1016/S1525-5050\(02\)00004-5](http://dx.doi.org/10.1016/S1525-5050(02)00004-5).
- Reuber, M., Howlett, S., Khan, A., Grünwald, R., 2007. Non-epileptic seizures and other functional neurological symptoms: predisposing, precipitating and perpetuating factors. *Psychomatics* 48, 230–238. <http://dx.doi.org/10.1176/appi.psych.48.3.230>.
- Ristić, A.J., Daković, M., Kerr, M., Kovačević, M., Parojčić, A., Sokić, D., 2015. Cortical thickness, surface area and folding in patients with psychogenic nonepileptic seizures. *Epilepsy Res.* 112, 84–91. <http://dx.doi.org/10.1016/j.eplepsyres.2015.02.015>.
- Schmahmann, J.D., Smith, E.E., Eichler, F.S., Filley, C.M., 2008. Cerebral white matter. *Ann. N. Y. Acad. Sci.* 1142 (1), 266–309. <http://dx.doi.org/10.1196/annals.1444.017>.
- Schneider, F., Bermpohl, F., Heinzl, A., Rotte, M., Walter, M., Tempelmann, C., ... Northoff, G., 2008. The resting brain and our self: self-relatedness modulates resting state neural activity in cortical midline structures. *Neuroscience* 157 (1), 120–131. <http://dx.doi.org/10.1016/j.neuroscience.2008.08.014>.
- Seminowicz, D.A., Mayberg, H.S., McIntosh, A.R., Goldapple, K., Kennedy, S., Segal, Z., Rafi-Tari, S., 2004. Limbic-frontal circuitry in major depression: a path modeling metanalysis. *NeuroImage* 22 (1), 409–418. <http://dx.doi.org/10.1016/j.neuroimage.2004.01.015>.
- Shin, L.M., Whalen, P.J., Pitman, R.K., Bush, G., Macklin, M.L., Lasko, N.B., ... Rauch, S.L., 2001. An fMRI study of anterior cingulate function in posttraumatic stress disorder. *Biol. Psychiatry* 50 (12), 932–942. [http://dx.doi.org/10.1016/S0006-3223\(01\)01215-X](http://dx.doi.org/10.1016/S0006-3223(01)01215-X).
- Sundararajan, T., Tesar, G.E., Jimenez, X.F., 2016. Biomarkers in the diagnosis and study of psychogenic nonepileptic seizures: a systematic review. *Seizure* 35, 11–22. <http://dx.doi.org/10.1016/j.seizure.2015.12.011>.
- Thompson, R., Isaac, C.L., Rowse, G., Tooth, C.L., Reuber, M., 2009. What is it like to receive a diagnosis of nonepileptic seizures? *Epilepsy Behav.* 14 (3), 508–515. <http://dx.doi.org/10.1016/j.yebeh.2008.12.014>.
- Turkeltaub, P.E., Eickhoff, S.B., Laird, A.R., Fox, M., Wiener, M., Fox, P., 2012. Minimizing within-experiment and within-group effects in activation likelihood estimation meta-analyses. *Hum. Brain Mapp.* 33 (1), 1–13. <http://dx.doi.org/10.1002/hbm.21186>.
- Van Den Heuvel, M.P., Pol, H.E.H., 2010. Exploring the brain network: a review on resting-state fMRI functional connectivity. *Eur. Neuropsychopharmacol.* 20 (8), 519–534. <http://dx.doi.org/10.1016/j.euroneuro.2010.03.008>.
- Varma, A.R., Moriarty, J., Costa, D.C., Gacinovic, S., Schmitz, E.B., Ell, P.J., Trimble, M.R., 1996. HMPAO SPECT in non-epileptic seizures: preliminary results. *Acta Neurol. Scand.* 94 (2), 88–92. <http://dx.doi.org/10.1111/j.1600-0404.1996.tb07035.x>.
- Vernooij, M.W., Ikram, M.A., Tanghe, H.L., Vincent, A.J., Hofman, A., Krestin, G.P., ... van der Lugt, A., 2007. Incidental findings on brain MRI in the general population. *N. Engl. J. Med.* 357 (18), 1821–1828. <http://dx.doi.org/10.1056/NEJMoa070972>.
- Whitwell, J.L., 2009. Voxel-based morphometry: an automated technique for assessing structural changes in the brain. *J. Neurosci.* 29 (31), 9661–9664. <http://dx.doi.org/10.1523/JNEUROSCI.2160-09.2009>.
- Wiseman, H., Reuber, M., 2015. New insights into psychogenic nonepileptic seizures 2011–2014. *Seizure* 29, 69–80. <http://dx.doi.org/10.1016/j.seizure.2015.03.008>.
- World Health Organization, 1992. *The ICD-10 Classification of Mental and Behavioural Disorders: Clinical Descriptions and Diagnostic Guidelines*. World Health Organization, Geneva.
- Zatorre, R.J., Fields, R.D., Johansen-Berg, H., 2012. Plasticity in gray and white: neuroimaging changes in brain structure during learning. *Nat. Neurosci.* 15 (4), 528–536. <http://dx.doi.org/10.1038/nn.3045>.